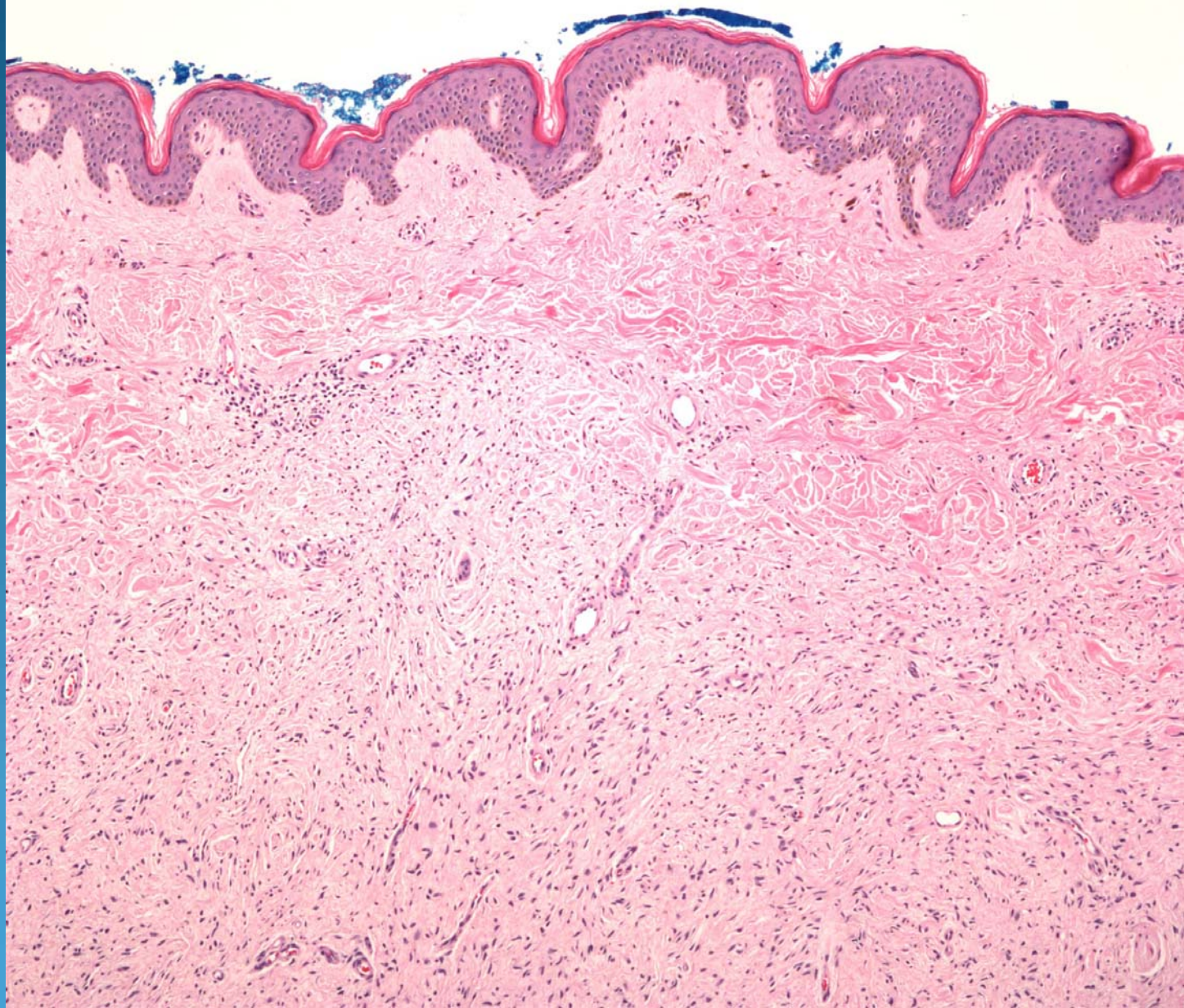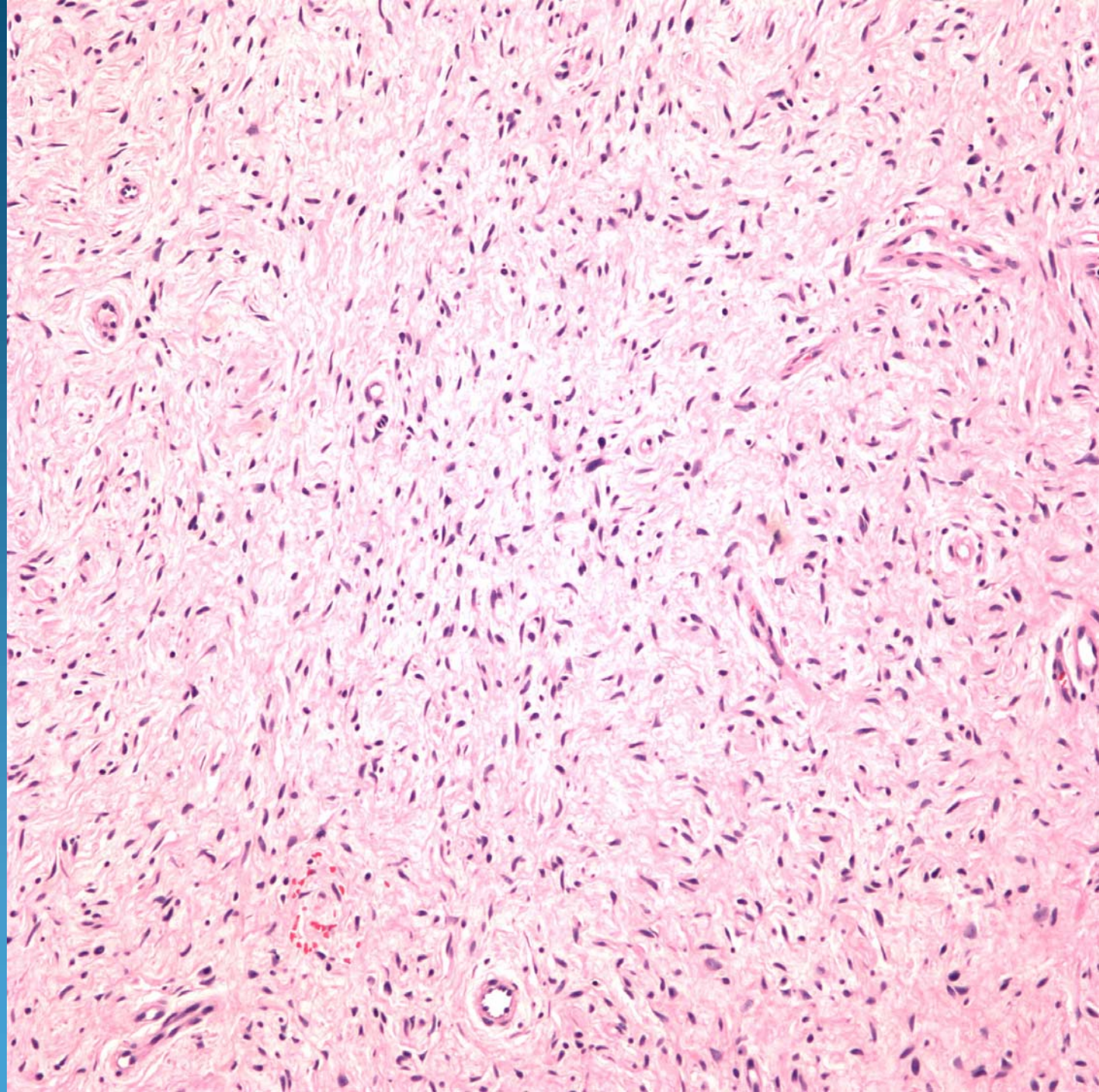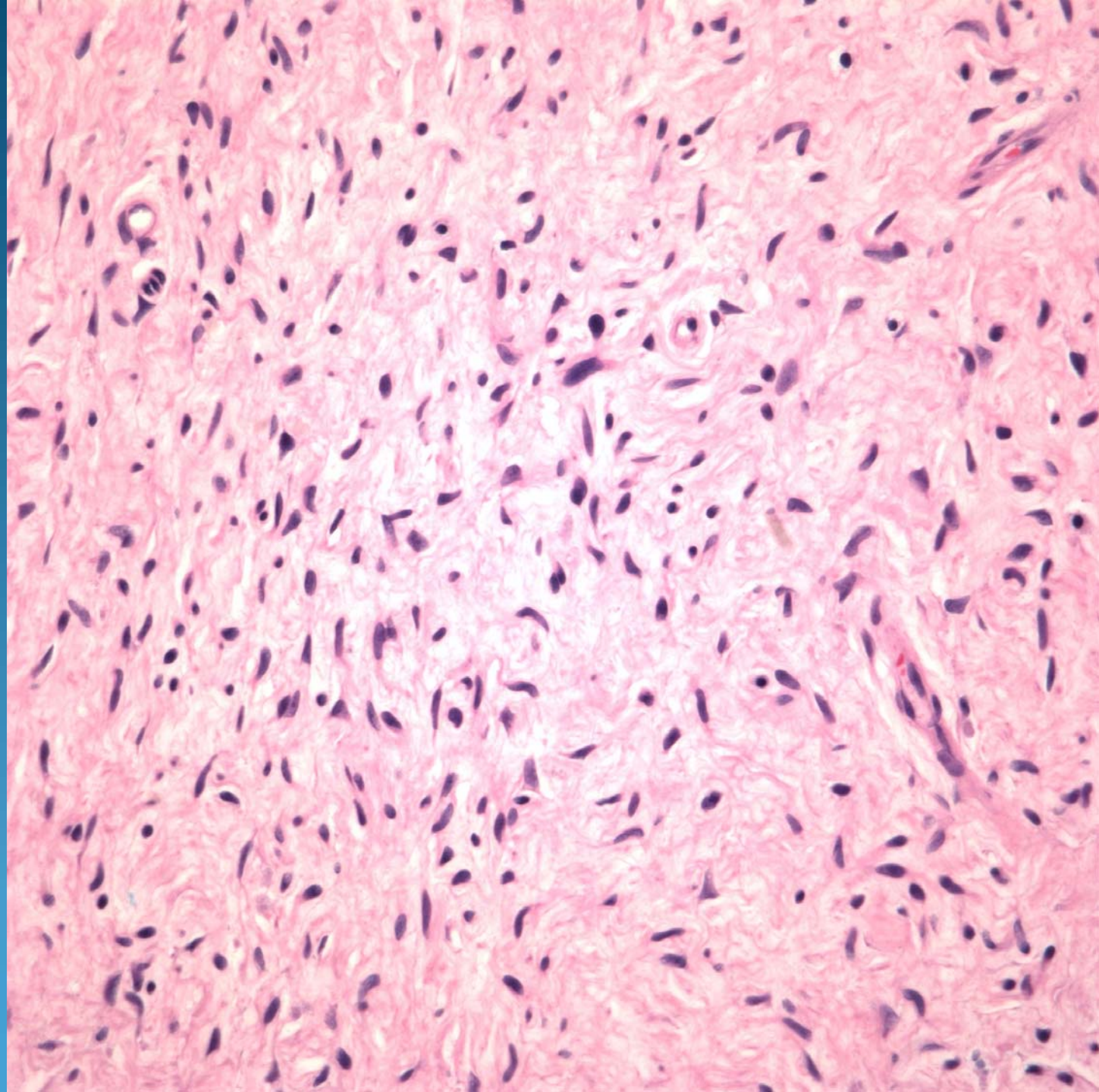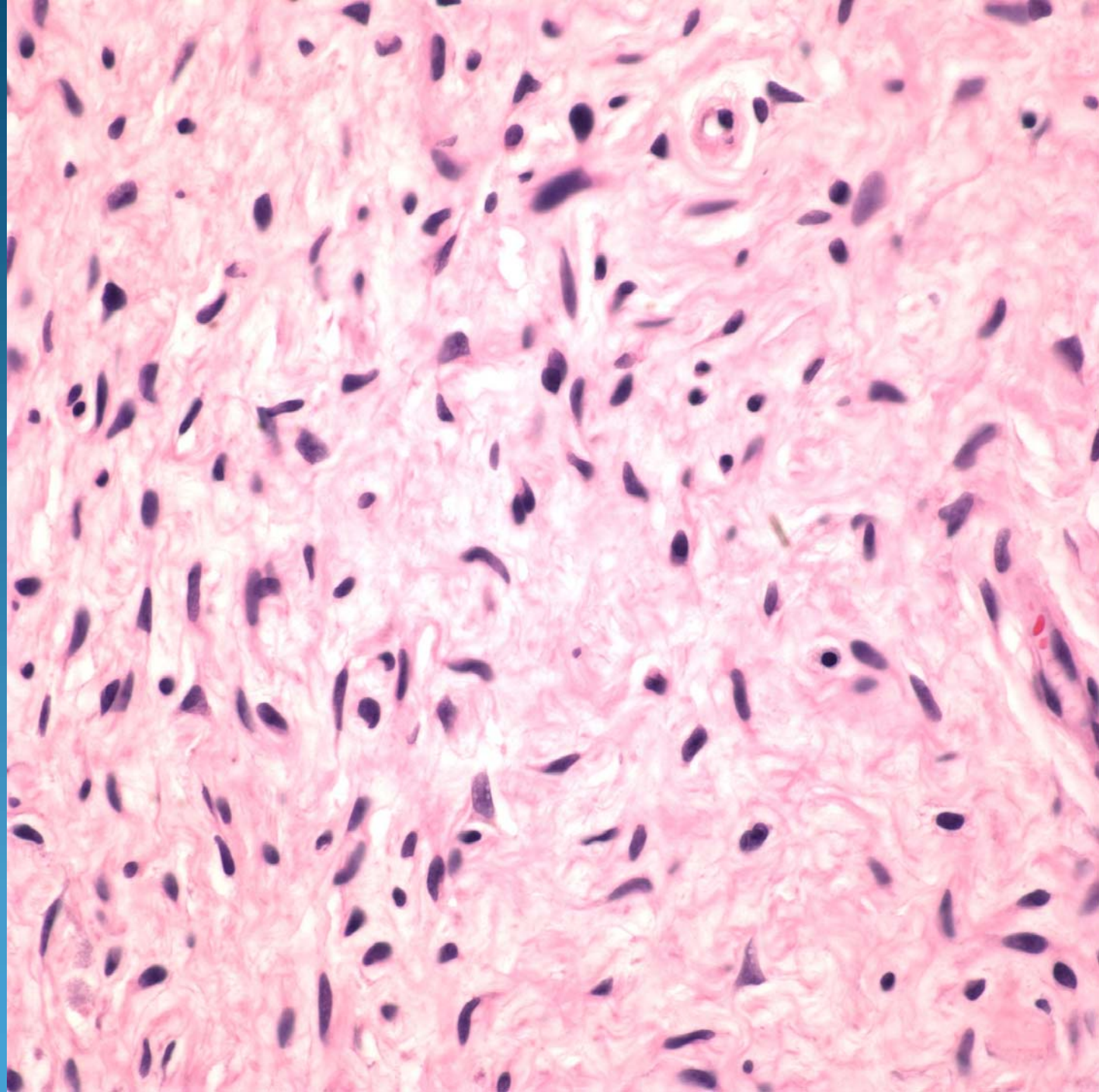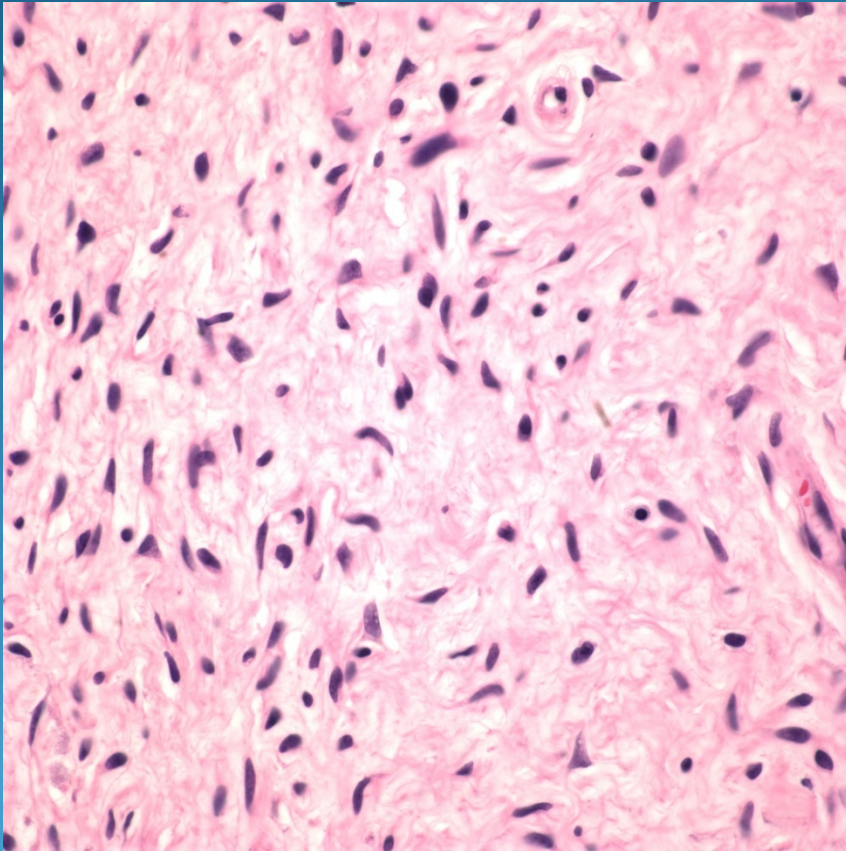


Neurofibroma

Pearls



- Moderately cellular non-encapsulated nodule
- Bland spindle cells with “bucket-handle” or wavy configuration
- Background stroma pale with mucin and increased mast cells
- May observe nerve roots